

## Case Report

# Graftless solution for multiple unfavorably placed implants using dynamic abutment® solutions: A case report with a 3-year follow-up

Chandrasekhar Nakka, Soujanya Kollipara, Kothuri Naga Ravalika

Dr. Sekhar's Dental Care and Implant Centre, Hyderabad, Telangana, India

### Abstract

The employment of implant-supported crowns and bridges has become a well-established and preferred approach in replacing missing teeth. A favorable implant position is mandatory to obtain good esthetic results and ideal emergence of screw access hole. Usually, unfavorably placed implants are the result of insufficient bone volume which leads to implant trajectory in the available bone. Once placed, they are restored giving a cement-retained prosthesis to avoid labial/buccal screw access holes. A graftless solution for this scenario may be using an angulated screw channel technology which corrects the prosthetic screw access hole emergence in an alternative direction which is more esthetic and acceptable. Dynamic Abutment® Solutions system is unique and exclusive and can be used as a true alternative to titanium-angulated abutments or customized Ti abutments designed through computer-aided design and computer-aided manufacturing technologies. The Dynamic Abutment® solutions system rectifies angulation issues with millimetric precision up to 30° with full freedom of movement. This case report explains a case where a two-implant supported fixed partial denture was employed in the esthetic zone using Dynamic Abutment® Solutions system with angulation rectification by a graftless procedure.

**Keywords:** Angulated screw channel, computer-aided design and computer-aided manufacturing, dental implants, graftless, screw retained

**Address for correspondence:** Dr. Chandrasekhar Nakka, D-136, Beside D Block Park, Madura Nagar, Hyderabad - 500 038, Telangana, India.  
E-mail: [drsekharcn@gmail.com](mailto:drsekharcn@gmail.com)

**Submitted:** 04-Oct-2019, **Revised:** 30-Oct-2019, **Accepted:** 22-Jun-2020, **Published:** 17-Jul-2020

### INTRODUCTION

With remarkable advancement in the past few years, implant dentistry has witnessed challenging issues concerning the materials and designs related to implants as well as implant abutments regarding achieving maximum clinical success rates.<sup>[1]</sup> The employment of implant-supported crowns and bridges has become a

well-established and preferred approach in replacing missing teeth.<sup>[2]</sup>

Screw-retained restorations are considered to be more favorable due to their ease of retrievability and to facilitate the treatment of any technical and biologic complications.<sup>[3]</sup> For screw retained restorations to be used, to obtain good esthetic results and ideal emergence of screw access hole, a

Access this article online	
Quick Response Code:	Website: <a href="http://www.j-ips.org">www.j-ips.org</a>
	DOI: 10.4103/jips.jips_362_19

This is an open access journal, and articles are distributed under the terms of the Creative Commons Attribution-NonCommercial-ShareAlike 4.0 License, which allows others to remix, tweak, and build upon the work non-commercially, as long as appropriate credit is given and the new creations are licensed under the identical terms.

**For reprints contact:** [reprints@medknow.com](mailto:reprints@medknow.com)

**How to cite this article:** Nakka C, Kollipara S, Ravalika KN. Graftless solution for multiple unfavorably placed implants using dynamic abutment® solutions: A case report with a 3-year follow-up. J Indian Prosthodont Soc 2020;20:331-4.

favorable implant position is mandatory.<sup>[4]</sup> An unfavorably placed implant may be a result of an improper positioning, tilting implants to avoid sensitive anatomical structures, or implants placed on best available bone width in the arch which make them out of line.<sup>[5]</sup> Such unfavorably placed implants are the result of insufficient bone volume which leads to implant trajectory in the available bone.

The implant-supported prosthesis planning should start much time before the implant placement surgery or even the choice of the implant itself. This is the concept of reverse planning. Previous research suggests to approach ideal implant positioning from a three-dimensional perspective.<sup>[6,7]</sup> It states that the most common error in implant placement is to angle it facially, which displaces the soft-tissue contours of the crown apically. A better solution for this scenario, where the grafting surgery can be avoided, may be using an angulated screw channel technology which corrects the prosthetic screw access hole emergence in an alternative direction which is more esthetic and acceptable.

Dynamic Abutment® Solutions system is unique and exclusive and can be used as a true alternative to titanium-angulated abutments or customized Ti abutments designed through computer-aided design and computer-aided manufacturing (CAD/CAM) technologies. The Dynamic Abutment® solutions system rectifies angulation issues with millimetric precision up to 30° with the full freedom of movement. This means, now, replacing any number of teeth is possible in almost any situation with a screw-retained restoration by a graftless procedure.

## CASE REPORT

A 19-year-old healthy female patient was presented to our clinic, with a complaint concerning about replacing her three missing anterior teeth.

The patient gave a history of trauma that resulted in the fracture of anterior teeth 11, 12, 21. The patient desired for a fixed and permanent replacement for her missing teeth which would be esthetically pleasing and long-lasting.

Before the treatment, patient consent form and a thorough history of all the medical conditions was taken systematically, and various medical tests were advised. The patient showed no medical history relevant to her chief complaint and upcoming treatment plan.

At the time of first visit, the patient had been using a removable partial denture in the upper anterior arch. As the patient desired for a fixed replacement, implant-supported

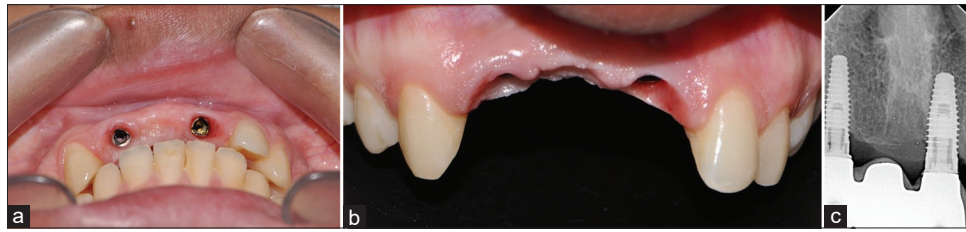fixed dental prosthesis (FDP) replacing the missing teeth was advised and planned. The importance of bone grafting was emphasized for better implants trajectory for which the patient was reluctant as it involves another surgery and waiting period. Placement of two implants in the trajectory of available bone was done [Figure 1a-c], and good primary stability was achieved. Immediate provisionalization was done with a screw retained acrylic FDP. The screw access hole was emerging at the labioinciso angle which was sealed with a composite resin. The primary purpose of provisionalization is to avoid social embarrassment and creating an emergency profile as replacement was to be done in the esthetic zone.

After 4 months of successful tissue healing, final impressions of the implants along with the opposing arch were made, and casts were poured to obtain the implant level. An optical scanner was used for scanning these poured casts to acquire the numerical models.


As the implants placed in this case had labial inclinations, the screw access holes would emerge labially causing unesthetic profile [Figure 2a-c]. The needed angulation corrections were determined using the CAD software which came out to be 25 degrees in 12 and 30 degrees in 21 [Figures 3a-c]. The CAD software allows the screw accesses of implants to be virtually moved more favorably to palatal side using DAS (Dynamic Abutment® Solutions) library. The virtual stereolithography file was sent for milling, and the CAM process fabricated the angulated screw channel zirconia-based FDP framework. The milled FDP framework was layered with emax ceramic layering material and later the entire unit was luted with resin cement onto the dynamic Tibase before delivery of the final prosthesis [Figure 4a and b]. This rectification allowed the screw accesses to emerge from the lingual side, which were earlier emerging from the labial side, solving the problem of unfavorably placed implants and giving a more esthetic outcome with all the added benefits of screw-retained prosthesis.[Figures 5a-d].

## DISCUSSION

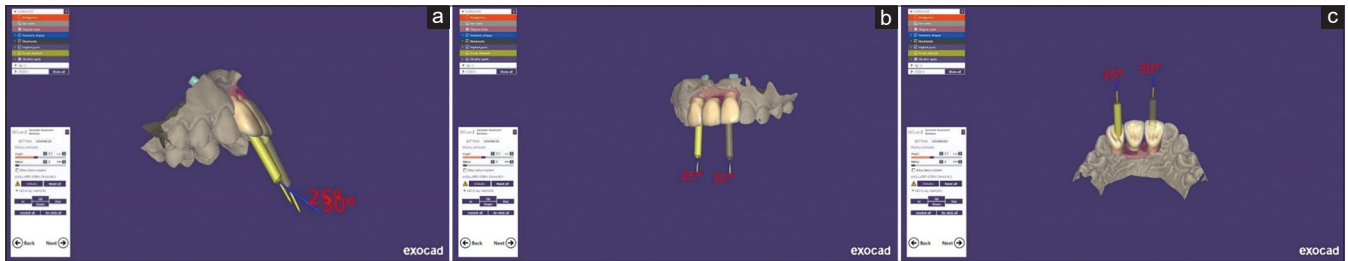
In this clinical report, a case where unfavorably placed implants resulting in labial screw emergence was managed by employing Dynamic Abutment® solution is described. Esthetics of implant-supported restorations is determined by the location of the implants placed.<sup>[8]</sup> Particularly, when screw-retained crowns are planned to be the prosthetic choice, surgeon should bring to the attention, the inclination of the implant fixture accordingly while planning the surgical procedure. This issue is usually not



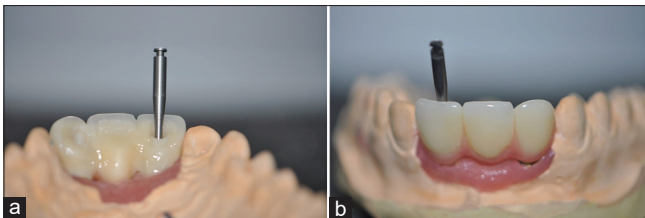
**Figure 1:** (a) Occlusal view after implants placement in 12 and 21. (b) Facial view after implants placement in 12 and 21. (c) Radiographic view after implants placement in 12 and 21



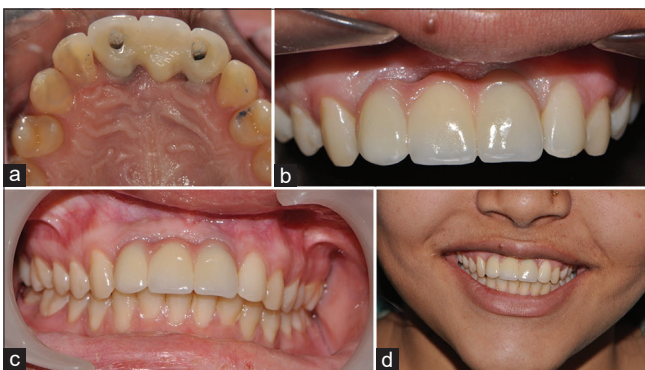
**Figure 2:** (a) Facial view of implants in 12 and 21 showing labial inclinations. (b) Dynamic abutment solutions screw driver. (c) Dynamic abutment Ti base



**Figure 3:** (a-c) Angulation rectification using computer-aided design and computer-aided manufacturing



**Figure 4:** (a and b) Milled prosthesis showing lingual screw emergences

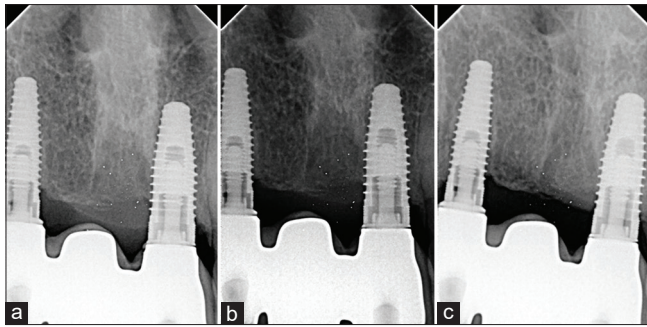


**Figure 5:** (a) Occlusal views of final screw-retained crown unit. (b-d) Facial views of final screw-retained crown unit

encountered with posterior implants, as they are positioned more axially in relation to the alveolus and tooth. However, it is problematic with anterior teeth as the implants need to be inclined lingually to allow screw emergence through the cingulum area of the restoration.<sup>[2]</sup>

CAD/CAM technology with its constant improvements has been challenging conventional methods in fabricating implant-supported prostheses and abutments. These techniques are being considered for the fabrication of implant-supported prostheses routinely in every clinical situation. The outcomes on using this technology show more precision than traditional fabrication techniques. An absolute adjustment that avoids alterations in the connection geometry with the implant during the production process of a prosthesis is well assured by this technique.<sup>[9]</sup>

Dynamic Abutment® System uses this technology for designing and milling screw-retained prosthesis. Dynamic TiBases® are a technological contribution to the digital treatment for the angulated screw channel systems



**Figure 6:** (a) Radiographic view of the screw-retained crown unit after a year follow-up. (b) Radiographic view of the screw-retained crown unit after 2 years follow-up. (c) Radiographic view of the screw-retained crown unit after 3 years follow-up

development using CAD/CAM technology. The ultimate aim of prosthetic dentistry is to restore patient's normal contour along with their function, comfort, esthetics, speech, and health.<sup>[10]</sup> What makes this technique, unique is the potential to achieve this aim. Implant-supported prostheses that are given using Dynamic Abutment® System have the advantages of screw-retained prosthesis that are its retrievability, esthetics, and comfortable maintenance in terms of hygiene and refittings.<sup>[11]</sup>

## CONCLUSION

After the final delivery of prosthesis, the patient was followed for 3 years at regular intervals [Figure 6a-1 year, b-2 years, c-3 years]. There were no technical or biological complications found due to the corrections of screw emergence. Using Dynamic Abutment® solutions for altering the emergence of prosthetic screw access hole in a direction which is more esthetic and acceptable in cases where rectification of entry of the screw due to an unfavorable implant placement is necessary. It presents a graftless solution which is better than using a cemented crown avoiding its cons and has advantages of screw-retained abutments.

## Declaration of patient consent

The authors certify that they have obtained all appropriate patient consent forms. In the form the patient(s) has/have

given his/her/their consent for his/her/their images and other clinical information to be reported in the journal. The patients understand that their names and initials will not be published and due efforts will be made to conceal their identity, but anonymity cannot be guaranteed.

## Financial support and sponsorship

Nil.

## Conflicts of interest

There are no conflicts of interest.

## REFERENCES

1. Shadid R, Sadaqa N. A comparison between screw- and cement-retained implant prostheses. A literature review. *J Oral Implantol* 2012;38:298-307.
2. Assaf M, Gharbyeh AZA. Screw-retained crown restorations of single implants: A step-by-step clinical guide. *Eur J Dent* 2014;8:563-70.
3. Sailer I, Mühlemann S, Zwahlen M, Hämmerle CH, Schneider D. Cemented and screw-retained implant reconstructions: A systematic review of the survival and complication rates. *Clin Oral Implants Res* 2012;23:163-201.
4. Ahmad M, Dhanasekar B, Aparna IN, Naim H. Replacement of missing anterior tooth using screw retained implant prosthesis in the esthetic zone: A case report with 3 years of follow up. *J Indian Prosthodont Soc* 2014;14:297-300.
5. Ramasamy M, Giri RR, Raja R, Subramonian K, Karthik CG, Narendrakumar R. Implant surgical guides: From the past to the present. *J Pharm Bioallied Sci* 2013;5:S98-102.
6. Grunder U, Gracis S, Capelli M. Influence of the 3-D bone-to-implant relationship on esthetics. *Int J Periodontics Restorative Dent* 2005;25:113-9.
7. Tarnow DP, Cho SC, Wallace SS. The effect of inter-implant distance on the height of inter-implant bone crest. *J Periodontol* 2000;71:546-9.
8. Martín WC, Pollini A, Morton D. The influence of restorative procedures on esthetic outcomes in implant dentistry: A systematic review. *Int J Oral Maxillofac Implants* 2014;29 Suppl: 142-54.
9. Kapos T, Evans C. CAD/CAM technology for implant abutments, crowns, and superstructures. *Int J Oral Maxillofac Implants* 2014;29 Suppl: 117-36.
10. Shetty S, Garg A, Shenoy KK. Principles of screw-retained and cement-retained fixed implant prosthesis: A critical review. *J Interdiscip Dent* 2014;4:123-8.
11. Dewan SK, Arora A, Sehgal M, Khullar A. Implant failures: A broader perspective. *J Dent Implants* 2015;5:53-8.